ORIGINAL RESEARCH

Comparative Evaluation of the Role of Macrogol–Propylene Glycol, Aloe Vera (Aloe Barbadensis Miller) and Distilled Water as a Vehicle for Triple Antibiotic Drugs in the Success of Lesion Sterilization and Tissue Repair in Primary Mandibular Molars

Avneet Dengre[1], Swati Garg[2], Ritu Namdev[3]

Abstract

Aim: To evaluate and compare the role of macrogol–propylene glycol (MP), aloe vera gel (Aloe barbadensis miller) and distilled water as a vehicle (mixing medium) for triple antibiotic drugs in the success of lesion sterilization and tissue repair (LSTR).

Materials and methods: Fifty-four primary mandibular second molars with irreversible pulpitis and poor prognosis in children aged 3–8 years were included in the study and were randomly divided into three groups (18 per group), in which LSTR was performed. Samples were grouped based on the vehicle used for mixing triple antibiotic drugs as macrogol–propylene glycol (Group A), aloe vera (Group B) and distilled water (Group C). Clinical evaluations were done at 3, 6, 9 and 12 months and radiographic evaluations at 6, 9 and 12 months.

Result: At the end of 12 months, 100% clinical and radiographic success was observed in Group B, while clinical and radiographic success rate in Group A was 82.35% and 88.24% respectively and both clinical, as well as radiographic success rate in Group C, was 81.25%. No statistically significant difference was seen in clinical as well as radiographic success rates ($p = 0.156$ and 0.176 respectively) among the three groups.

Conclusion: Clinical and radiographic outcomes suggested that all of the three mixing media used in the study could be regarded as a suitable vehicle for 3 Mix in LSTR. However, better results were found when aloe vera was used as a mixing medium.

Keywords: Aloe vera, Lesion sterilization and tissue repair, Pulpectomy.

Journal of South Asian Association of Pediatric Dentistry (2018): 10.5005/jp-journals-10077-3010

Introduction

The Cariology Research Unit of Niigata University School of Dentistry, Japan, has developed the concept of LSTR[1] or non-instrumental endodontic treatment (NIET), in which combination of antibacterial drugs are used for disinfection of root canals and associated periapical lesions. Primary teeth often present with infected root canals, especially with periradicular tissue involvement. LSTR is a feasible treatment option, especially in teeth with poor prognosis or when conventional pulpectomy is undesirable, to preserve such teeth until their exfoliation.

In LSTR, a combination of three antibiotics, i.e., ciprofloxacin, metronidazole and minocycline (3 Mix) delivered via vehicle (mixing medium) comprising of macrogol and propylene glycol (MP) together called as 'Triple antibiotic paste', is used for disinfection of root canals[1]. 3 Mix is found to be effective in sterilizing carious lesions, necrotic pulps and infected root dentine of primary teeth[2,3].

However, the role of a suitable vehicle for delivering triple antibiotic drugs into infected root canals is imperative for the success of LSTR. Mixing medium plays an important role in determining penetration of medicaments to the deeper inaccessible areas in root canal such as root dentine and cementum, even in the presence of anatomical aberrations such as fins, isthmuses and blocked canal[2]. Diffusion into the surrounding periradicular tissues may also be an advantage. It also affects the workability of the mix. Propylene glycol (1,2-propanediol), a dihydric alcohol has the potential for use in LSTR. Its chemical formula is CH_3CH (OH) CH_2OH, and it has a molecular weight of 76.09[2]. Cruz *et al*. suggested vehicles like Macrogol-Propylene glycol increases the penetration of antibiotics and carry the medicament deep into the dentinal tubules, thus aid in effective eradication of microbial load[2]. However, certain studies had shown the presence of some resistant microbial strains within root canals and in dentinal tubules, e.g., *Enterococcus faecalis*, *Candida albicans* etc[2,4]. This may be because of inadequate penetration of drug to deeper inaccessible areas in primary root canal as the efficiency of medicament depends on the type of vehicle used[5]. Thus, further studies are required to bring to light more effective and efficacious vehicles for 3 Mix. Guided by this, aloe vera gel was used as one of the vehicles in this study.

[1,2]Postgraduate Student, [3]Associate Professor

[1-3]Department of Pedodontics and Preventive Dentistry, Postgraduate Institute of Dental Sciences, Rohtak, Haryana, India

Corresponding Author: Avneet Dengre, Postgraduate Student, Department of Pedodontics and Preventive Dentistry, Postgraduate Institute of Dental Sciences, Rohtak, Haryana, India, Phone:+918800409303, e-mail: avneetd1@gmail.com

How to cite this article: Dengre A, Garg S *et al*. Comparative Evaluation of the Role of Macrogol–Propylene Glycol, Aloe Vera (Aloe Barbadensis Miller) and Distilled Water as a Vehicle for Triple Antibiotic Drugs in the Success of Lesion Sterilization and Tissue Repair in Primary Mandibular Molars. J South Asian Assoc Pediatr Dent 2018;1(2):33-38.

Source of support: Nil

Conflict of interest: None

© The Author(s). 2019 Open Access This article is distributed under the terms of the Creative Commons Attribution 4.0 International License (http://creativecommons.org/licenses/by/4.0/), which permits unrestricted use, distribution, and non-commercial reproduction in any medium, provided you give appropriate credit to the original author(s) and the source, provide a link to the Creative Commons license, and indicate if changes were made. The Creative Commons Public Domain Dedication waiver (http://creativecommons.org/publicdomain/zero/1.0/) applies to the data made available in this article, unless otherwise stated.

Aloe vera *(Aloe barbadensis miller)* is a very useful herbal medicine in itself. It is a source of 19 out of 20 essential amino acids which are required by our body, and these amino acids help in the proper functioning of our complex enzyme system. Aloe vera serves to be a reservoir of vitamins including vitamin A, B, C, E, and folic acid. It is also perceived to be a good antiviral, antibacterial and antifungal agent, as the inner gel is surrounded by polysaccharides which defend our body from all such attacks. It is an effective anti-inflammatory agent with analgesic properties[3]. It can also be used as an intracanal medicament and sedative dressing in root canals[6]. Aloe vera acts by inhibiting the arachidonic acid pathway via cyclooxygenase (COX) inhibition resulting in resolution of inflammation[7]. Aloe vera has also shown an antimicrobial effect even against resistant microorganisms found in pulp space such as *Candida albicans* and *Enterococcus faecalis*[8].

There had been studies on the efficacy of propylene glycol and distilled water as delivery vehicles for 3 Mix in LSTR[2]. But the potential of aloe vera has been untapped in this regard till date. However, there are numerous studies on the clinical use of aloe vera in various conditions like lichen planus, aphthous stomatitis, pulpotomy of primary teeth, prevention of dry socket, obturation of primary teeth, disinfection of irrigation units, bleeding and painful gums, disinfection of gutta-percha cones, burning mouth, etc.[9] Thus, this prospective single-blinded randomized control trial was designed to evaluate the role of Macrogol–Propylene glycol, aloe vera and distilled water as a vehicle for 3 Mix in the success of LSTR.

Materials and Methods

This monocentric, parallel, single-blinded study with 1:1:1 allocation ratio included fifty-four primary mandibular second molars with irreversible pulpitis and poor prognosis. Children aged 3–8 years were selected from the outpatient setting of the Department of Pedodontics and Preventive Dentistry of the institution based on inclusion criteria.

Inclusion Criteria

- Primary mandibular molar with irreversible pulpitis
- Teeth showing furcation radiolucency without involving the underlying tooth germ.
- Teeth showing evidence of internal and external root resorption.

Exclusion Criteria

- Primary mandibular molar with pulpal floor perforation.
- Any known allergy to drugs used in the study.

Sample Size Calculation

In the present study, taking the radiological and clinical success rates of LSTR, the sample size was calculated with 95% power and 5% level of significance with 95% confidence interval, using formula:

$$n \geq \frac{2\,(Z\alpha + Z\beta)^2 \times p \times q}{d^2}$$

$$\text{where } p = \frac{p1 + p2}{2}$$

$$q = 1\text{-}p$$

$$p1 = 94.73\%,\ p2 = 33.33\%$$

Along with 10% attrition and was determined to be 18 per group. It was consistent with the nearly similar study performed by Agarwal *et al.*[10]

Randomization

Samples were randomized into three groups viz. Group A, Group B and Group C by simple random sampling technique using computer-generated random table and allocation concealment using central randomization. In Group A (n = 18) subjects received 3 Mix antibiotic (ciprofloxacin 500 mg, minocycline 100 mg and metronidazole 400 mg) mixed with MP as medium; in Group B (n = 18) aloe vera gel *(aloe barbadensis miller)* was used as medium and in Group C (n = 18) antibiotics were mixed in distilled water.

Preparation and Procedure

The drugs used were ciprofloxacin (Ciplox 500; Cipla Ltd, Sikkim, India), metronidazole (Metrogyl 400; JB Chemicals, Rajpipla, India) and minocycline (Minoz 100; Sun Pharma, Dewas, India). Ciprofloxacin, metronidazole, and minocycline were pulverized separately before the procedure, and mixed in the ratio of 1:3:3 respectively as 3 Mix[1]. This 3 Mix was then mixed with MP (Group A), aloe vera gel (Group B) and distilled water (Group C) in the ratio of 7:1 (3 Mix: Mixing medium)[11]. Aloe vera gel was freshly obtained each time from plant leaf before treatment of subjects in the respective group. The paste was then used for intervention and the unused material was discarded at the end of office hour[10].

Local anesthesia, if needed, was administered before the procedure using lignocaine HCl 2% with 1:100,000 adrenaline. The tooth was then isolated using rubber dam, and after access opening, access cavity was sufficiently enlarged followed by removal of all accessible necrotic pulp using sterile spoon excavator and subsequent irrigation with sodium hypochlorite 0.5% and normal saline. The pulp chamber was thoroughly dried, and a layer of dentin bonding agent (Scotchbond, 3M ESPE, USA) was applied on the walls of the pulp chamber to prevent coronal discoloration because of minocycline. The freshly prepared 3 Mix was then placed over the pulpal floor, followed by restoration with glass ionomer cement (Fuji IX, GC, Tokyo, Japan). The teeth were finally restored with stainless steel crowns (3M ESPE) as permanent restoration after fifteen days as complete sterilization of root canals is achieved within 2 weeks[5], except in patients either with known nickel allergy or noncompliance of parents/patient.

Clinical and Radiographic Evaluation

Clinical evaluations were performed at 3, 6, 9 and 12 months for assessment of pain (Faces pain scale-revised), mobility, abscess and radiographic evaluations with IOPA using Endoray II film holder (Dentsply, UK) were made at 6, 9 and 12 months for visualizing changes in furcation radiolucency and bone formation in furcation area. Clinical and radiographic evaluation was performed by two independent investigators and operator. Investigators, who had previously been calibrated against a set of 100 reference teeth assessed radiographs blindly using magnification by a factor of 2. A third observer was consulted in case of disagreement. The assessment of concordance between the investigators was depicted by the Kappa coefficient (0.811 for clinical and 0.767 for radiographic calibration) with a 95% confidence interval.

Success Criteria

Clinical success criteria were the absence of pathological clinical signs and symptoms (pain, abscess/sinus, and/or abnormal mobility). Presence of one or more of the above mentioned clinical signs was considered as a failure. Radiographically, resolution of furcation radiolucency was considered as a success (Fig. 1).

Figs 1A to D: Radiographs preoperative, at 6, 9 and 12 months showing healing of furcation radiolucency. (A) Preoperative; (B) 6 months; (C) 9 months; (D) 12 months

Other radiographic findings such as internal resorption and pulp canal obliteration were also recorded but not analyzed statistically as none of the samples showed any change in this regard at subsequent follow-ups.

Statistical Methods

The data were analyzed using IBM SPSS Statistics for Windows (22.0.0, IBM, NY, USA). The p value ≤ 0.05 was taken to evaluate statistical significance. Intergroup comparison was made using the Chi-square test.

Ethical Aspect

This study received approval from the human research ethics committee (certificate number: PGIDS/IEC/2016/83) and was conducted in compliance with the precepts stipulated in the Declaration of Helsinki. The legal guardians of the children signed a statement of informed consent before the data collection process.

Results

In Group B, the postoperative assessment revealed resolution of furcation radiolucency in all the teeth along with the disappearance of clinical signs and symptoms, while bone formation was evident in 27.78% of teeth at the end of 12 months. Whereas, in Group A, at the end of 12 months, pain resolved in 82.35% of the patients, abscess/sinus and mobility resolved in 88.24%, furcation radiolucency healed in 88.24%, while bone formation was evident in 17.65% of the patients. Group C also presented with resolution of pain in 81.25% of teeth, mobility and abscess in 87.50% of teeth along with healing of furcation radiolucency in 81.25% of teeth and bone formation was not evident in any tooth (Table 1).

Intergroup Comparison

At preoperative evaluation, there was no significant difference between groups with respect to the presence of pain ($p = 0.317$), mobility ($p = 0.509$), abscess ($p = 0.892$) and furcation radiolucency ($p = 0.301$). At postoperative evaluation, there was no statistically significant difference in clinical as well as radiographic success rates ($p = 0.156$ and 0.176, respectively) among the three groups, with 82.35% (14 teeth) and 88.24% (15 teeth) clinical and radiographic success rate respectively in Group A, 100% (18 teeth) clinical as well as radiographic success rate in Group B and 81.25% (13 teeth) clinical as well as radiographic success rate in Group C (Table 2).

Discussion

Fifty-four primary mandibular second molars with irreversible pulpitis and poor prognosis were selected using set inclusion criteria. However, three samples were lost during follow up, one in Group A after 6 months follow up and two in Group C after 6 and 9 months follow-up respectively (Flow chart 1). Our rationale for selecting only lower molars was to be able to identify radiographic pathology and healing more precisely because of the limited

Table 1: Frequency of clinical signs and symptoms preoperatively and postoperatively at 12 months follow-up and radiographical signs and symptoms preoperatively and postoperatively at 6 and 12 months follow-up

Parameters	*Time*	*Group A n (%)*	*Group B n (%)*	*Group C n (%)*	*p values*
Clinical					
Pain	Pre	14 (77.78)	16 (88.89)	17 (94.44)	0.317
	12 m	3 (17.65)	0 (0)	3 (18.75)	0.156
Abscess/sinus	Pre	15 (83.33)	14 (77.78)	14 (77.78)	0.892
	12 m	2 (11.76)	0 (0)	2 (12.50)	0.305
Mobility	Pre	9 (50.00)	6 (33.33)	9 (50.00)	0.509
	12 m	2 (11.76)	0 (0)	2 (12.50)	0.305
Radiographic					
Furcation R/L	Pre	14 (77.78)	14 (77.78)	17 (94.44)	0.301
	6 m	2 (11.11)	0 (0)	2 (11.11)	0.340
	12 m	2 (11.76)	0 (0)	3 (18.75)	0.176
Bone formation	6 m	1 (5.56)	2 (11.11)	0 (0)	0.347
	12 m	3 (17.65)	5 (27.78)	0 (0)	0.081

(Pre- preoperatively, m- months, Group A: 3 Mix- Macrogol–Propylene glycol, Group B: 3 Mix- Aloe vera, Group C: 3 Mix- Distilled water, n-number of teeth, %- percentage of sample, R/L- Radiolucency. Comparisons were made using Chi-square test. *P* value less than 0.05* was considered statistically significant.)

Table 2: Comparison of clinical and radiographic success rate

	Clinical Success				*Radiographic Success*			
Follow-up period	*Group A n (%)*	*Group B n (%)*	*Group C n (%)*	*p value*	*Group A n (%)*	*Group B n (%)*	*Group C n (%)*	*p value*
3 months	16(88.89)	18(100)	15(83.33)	0.214	–	–	–	–
6 months	15(83.33)	18(100)	17(94.44)	0.151	16(88.89)	17(94.44)	17(94.44)	0.763
9 months	14(82.35)	18(100)	16(94.12)	0.139	15(88.24)	18(100)	16(94.12)	0.328
12 months	14(82.35)	18(100)	13(81.25)	0.156	15(88.24)	18(100)	13(81.25)	0.176

(m- Months, n- number of teeth, %- percentage of sample, Gp- Group, - signifies no statistics were computed. Comparisons were made using Chi-square test. *P* value less than 0.05* was considered statistically significant)

overlapping of lower permanent tooth buds and primary molar roots. Both maxillary and mandibular molars were included in the study by Nakornchai *et al*.[12], Takushige *et al*.[13], and Prabhakar *et al*.[14] whereas; Trairatvorakul *et al*.[15] and Agarwal *et al*.[10] included primary mandibular molars only in their study. Children from age group 3–8 years were selected in the present study. The lower limit was set at 3 years due to lack of cooperation in the younger children and the upper limit was set at 8 years as 3/4th root length still remains till this age during physiologic root resorption.

The procedure followed for LSTR was similar to that followed by Takushige *et al*.[13] and Pinky *et al*.[16], as root canal preparation was kept minimally possible following the principle of non-instrumental endodontic treatment[3]. The mix was used as a medicament and mixed with a vehicle, i.e., MP (Group A), aloe vera gel (group B) and distilled water (Group C). There had been studies on the efficacy of MP and distilled water as delivery vehicles for 3 Mix in LSTR[2]. However, this study was aimed towards assessing the relative success of aloe vera gel as a 3 Mix vehicle with MP and distilled water. Aloe vera *(aloe barbadensis miller)*, being a useful herbal medicine in itself proved its worth in various oro-dental problems because of its antiviral, antibacterial, and antifungal properties. Aloe vera acts by inhibiting the arachidonic acid pathway via cyclooxygenase (COX) inhibition resulting in resolution of in ammation[7]. The rationale behind using aloe vera in combination with 3 Mix was to prevent failure of treatment due to the presence of resistant strains, as aloe vera has also shown an antimicrobial effect even against resistant microorganisms found in pulp space such as *Candida albicans* and *Enterococcus faecalis*[17].

Analysis of results showed that in group A, the clinical success rate at the end of 3 months was found to be 88.89%, whereas Takushige *et al*[1]. observed clinical success rate of 100%. This could be partly due to the fact that they performed re-treatment with 3 Mix-MP of the cases which reported with signs and symptoms. At 6 months follow up, the success rate was documented to be 83.33%, whereas Prabhakar *et al*.[14] observed a 96.7% success rate. At 12 months follow up, the clinical success of 82.35% was noted, whereas the success rate of 91% and 93.3% was documented by Takushige *et al*.[13] and Prabhakar *et al*.[14] respectively. Radiographically, evidence of bone formation in the furcation area was seen in 17.65% samples after 12 months. The high success rate in Group A may be due to hygroscopic properties of propylene glycol, resulting in sustained release of intracanal medicaments for a prolonged duration[2]. Propylene glycol though, being vicious, possesses low surface tension which may have facilitated deeper penetration of drugs in dentinal tubules[2].

In group B, clinical success at 3, 6, 9 and 12 months follow-up was found to be 100%. The reason for the high success rate could be antibacterial, antifungal, anti-inflammatory properties of aloe vera as suggested by Balaji *et al*.[18] Aloe vera gel contains active ingredients such as anthraquinones, tannins, myristic acid, curcumin, nimbidin, specific glycoproteins and aloesin-related compounds which impart antibacterial as well as anti-inflammatory

Flow chart 1: Consort flow chart of participants throughout the trial

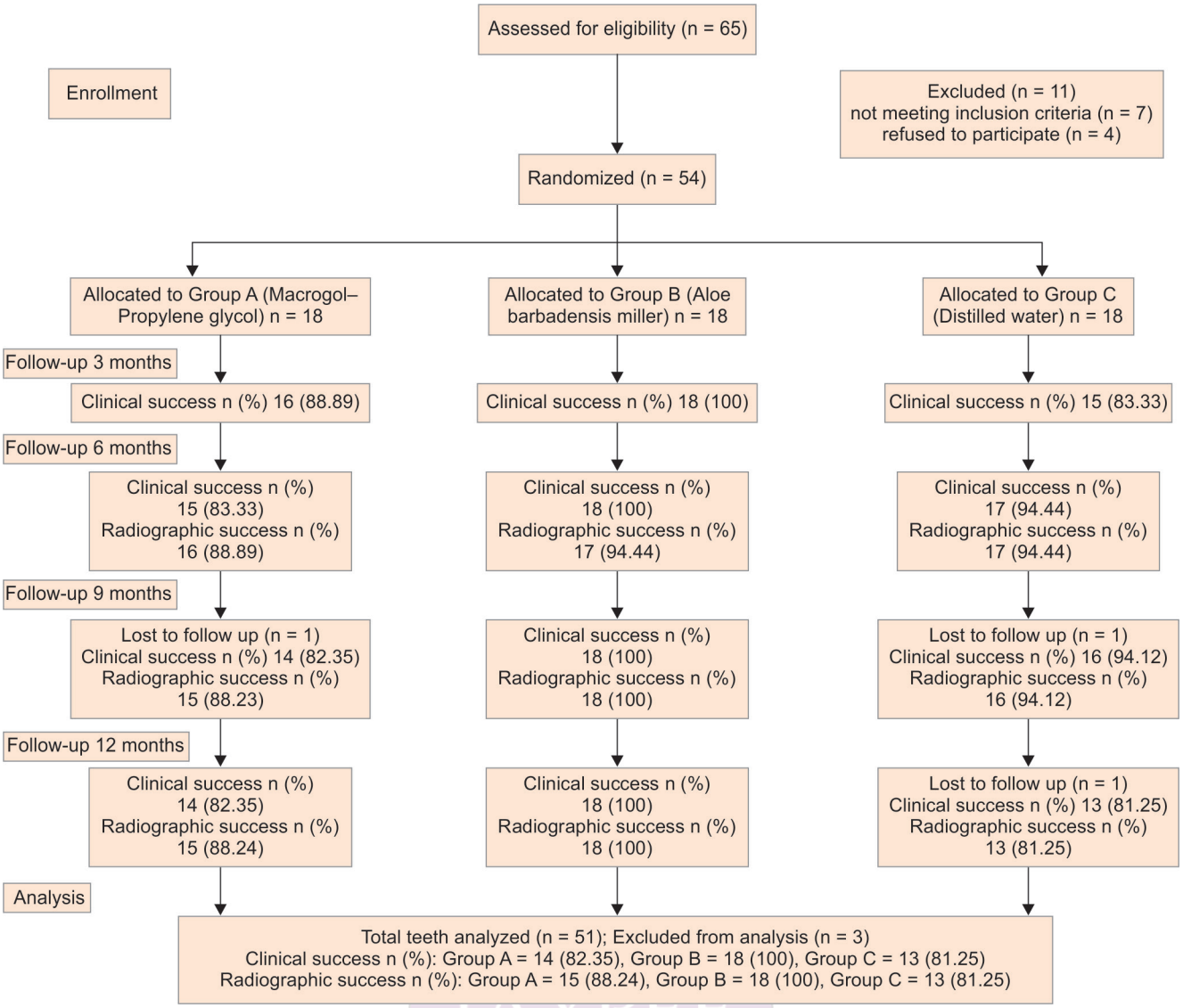

properties[6]. Radiographically, healing of furcation radiolucency was seen in 100% cases which were statistically significant as compared to Group C ($p = 0.05$). Bone formation in the furcation area was observed in 27.78% samples after 12 months which showed a statistically significant difference compared to Group C ($p = 0.022$). The results suggested 100% clinical and radiographic success when 3 Mix was mixed with aloe vera which was on the higher side as compared to 86.67% and 73.34% clinical and radiographic success respectively, as reported by Khairwa *et al.*[3] They reported the presence of pain in 13.33% and tenderness to percussion in 6.66% of their samples. This could be due to the fact that they mixed aloe vera with zinc oxide Eugenol and the deleterious effect of eugenol on periradicular tissues might have led to postoperative symptoms in few of their samples. The high success rate in this group owes to better physical properties of aloe vera gel as a vehicle, i.e. basic pH around 7.5 and inherent antimicrobial properties. This is consistent with the study done by Bhardwaj *et al.* which reported 80% microbial suppression, especially *E. faecalis*[19].

In group C, the clinical and radiographic success rate was 81.25%. However, bone formation was not evident in any of the samples. The reason for the lower success rate compared to groups A and B may be because distilled water is an aqueous medium with high viscosity and surface tension resulting in a high degree of solubility, when the paste formed by its combination with the medicament comes in direct contact with tissue and tissue fluids and hence, leading to its rapid solubilization and resorption by tissue macrophages[2].

All the teeth presented with persistent clinical and radiographic signs and symptoms were considered failure and thus, extracted followed by space maintainers. The shortcoming of the present study is the shorter follow-up period, i.e., 12 months.

Conclusion

After assessment of clinical and radiographic parameters for 12 months, it can be concluded that primary mandibular molars with irreversible pulpitis and poor prognosis can be treated with 3 Mix effectively by mixing in any of the three vehicles used in the study. However, clinical and radiographic success was on the higher side when 3 Mix was delivered via aloe vera.

However, periodic follow-ups are recommended until the exfoliation of teeth to further ascertain the efficacy of Lesion Sterilization and Tissue Repair and to properly assess the role of mixing mediums in the success of LSTR.

References

1. Takushige T, Cruz E, Moral A, Hoshino E. Endodontic treatment of primary teeth using a combination of antibacterial drugs. Int Endod J. 2004;37(2):132-138.
2. Cruz EV, Kota K, Huque J, Iwaku M, Hoshino E. Penetration of propylene glycol into dentine. Int Endod J. 2002;35(4):330-336.
3. Khairwa A, Bhat M, Sharma R, Satish V, Maganur P, Goyal AK. Clinical and radiographic evaluation of zinc oxide with aloe vera as an obturating material in pulpectomy: An in vivo study. J Indian Soc Pedod Prev Dent. 2014;32(1):33-38.
4. Lakhani AA, Sekhar KS, Gupta P, Tejolatha B, Gupta A, Kashyap S. *et al*. Efficacy of Triple Antibiotic Paste, Moxifloxacin, Calcium Hydroxide And 2% Chlorhexidine Gel in elimination of E. Faecalis: An in vitro Study. J Clin Diag Res. 2017;11(1):6-9.
5. Reddy GA, Sridevi E, Sai Sankar AJ, Pranitha K, Gowd MJ, Vinay C. Endodontic treatment of chronically infected primary teeth using triple antibiotic paste: An in vivo study. J Conserv Dent. 2017; 20(6):405-410.
6. Neena IE, Ganesh E, Poornima P, Korishettar R. An ancient herb aloevera in dentistry: A review. J Oral Res Rev. 2015;7(1):25-30.
7. Vazquez B, Avila G, Sequra D, Escalante B. Antiinflammatory activity of extracts from Aloe vera gel. J Ethnopharmacol. 1996;55(1):69-75
8. Sureshchandra B, Kumar AJ. Antibacterial efficacy of aloe vera extract on resistant antimicrobial strains in endodontics. Endodontology. 2011;23(1):56-60.
9. Tayal E, Sardana D, Indushekhar KR, Saraf BG, Sheoran N. Current perspectives on use of aloe vera in dentistry. European J Med Plants. 2014;4(12):1408-1419.
10. Agarwal M, Das UM, Vishwanath D. A comparative evaluation of non-instrumentation endodontic techniques with conventional ZOE pulpectomy in deciduous molars: An *in vivo* study. World J Dent. 2011;2(3):187-192.
11. Hoshino E, Kurihara-Ando N, Sato I, Uematsu H, Sato M, Kota K. *et al*. *In vitro* antibacterial susceptibility of bacteria from infected root dentin to a mixture of ciprofloxacin, metronidazole and minocycline. Int Endod J. 1996;29(2):125-130.
12. Nakornchai S, Banditsing P, Visetratana N. Clinical evaluation of 3Mix and Vitapex as treatment options for pulpally involved primary molars. Int J Paediatr Dent. 2010;20(3):214-221.
13. Takushige T, Cruz EV, Moral MAA, Hoshino E. Non-surgical treatment of pulpitis, including those with history of spontaneous pain, using a combination of antibacterial drugs. J LSTR Ther. 2008;7(1):1-5.
14. Prabhakar AR, Sridevi E, Raju OS, Satish V. Endodontic treatment of primary teeth using combination of antibacterial drugs: An *in vivo* study. J Indian Soc Pedod Prevent Dent. 2008;26(5):5-10.
15. Trairatvorakul C, Detsomboonrat P. Success rate of a mixture of ciprofloxacin, metronidazole and minocycline antibiotics used in the NIET of primary mandibular molars with carious pulpal exposure. Int J Ped Dent. 2012;22(3):217-227.
16. Pinky C, Shashibhushan KK, Subbareddy VV. Endodontic treatment of necrosed primary teeth using two different combinations of antibacterial drugs: An *in vivo* study. J Indian Soc Pedod Prev Dent. 2011;29(2):121-127.
17. Tonea A, Badea M, Voduar D, Oana L, Sava S. Antibacterial and antifungal activity of endodontic intracanal medications. Clujul Medical. 2017;90(3):344-347.
18. Balaji P, Jagtap K, Lau H, Bansal N, Thajuraj S, Sodhi P. Comparative evaluation of antimicrobial effect of herbal root canal irrigants (Morinda citrifolia, Azadirachta indica, Aloe vera)with sodium hypochlorite: An in vitro study. J Int Soc Prevent Comm Dent. 2016;6(3):196-199.
19. Bhardwaj A, Ballal S, Velmurugan N. Comparative evaluation of the antimicrobial activity of natural extracts of Morinda citrifolia, papain and aloe vera (all in gel formulation), 2% chlorhexidine gel and calcium hydroxide, against Enterococcus faecalis: An *in vitro* study. J Conserv Dent. 2012;15(3):293-297.

JAYPEE